

## CHAPTER 7

### RECTO-VAGINAL FISTULAS AND SPHINCTER TEARS

Section 7.1A: RVF: Trans-vaginal repair
Section 7.1B: RVF: Trans-perineal repair
Section 7.2: RVF: Trans-vaginal repair: circumferential defects
Section 7.3: RVF: Trans-abdominal repair
Section 7.4: RVF: Trans-abdominal repair: circumferential defects
Section 7.5: Anal sphincter tear repair
Section 7.6: RVF with anal sphincter tear repair

#### DIAGNOSIS OF RECTO-VAGINAL FISTULAS (RVF)

In most cases, the diagnosis of an RVF is made on digital rectal and vaginal examination. Occasionally if a patient complains of passing flatus or stool per vagina but no fistula is evident, a dye test is necessary. This is more likely if there is dense scarring with posterior bands (see Fig. 1.4) so that the RVF is hidden in the scar.

- Inject 200 ml of dye through a naso-gastric tube or a Foley catheter passed 10 cm into the rectum. If necessary a swab is used to compress the anus so that the dye does not leak out. Another option is to inflate the Foley balloon to keep the dye in.
- Not uncommonly, the diagnosis is only made when flatus is seen coming as bubbles through the blood/urine in the posterior vagina when operating for a VVF.
- A probe can be passed vaginally into the fistula and palpated rectally. Alternatively, you can pass the probe rectally and palpate vaginally. With large fistulas, the red rectal mucosa is distinguished from the paler pink vaginal skin on speculum examination.

#### CAUSES OF RVF

There are two main groups:

- (a) *RVF combined with VVF*: these are due to prolonged obstructed labour and are usually at least 3 cm above the dentate line. The repair technique is similar to VVFs. The following (section 7.1 to 7.4) refers mainly to this type of RVF which represents a more severe injury process than does an isolated VVF. The accompanying VVF is usually large and more commonly circumferential, and there is more vaginal scarring.
- (b) *Isolated RVF*:
  - RVFs due to incomplete healing of a 4th degree perineal tear (see section 7.5).
  - RVF due to sexual or other trauma.
  - RVFs due to obstructed labour only occur on rare occasions without a VVF.
  - RVF related to infections, especially associated with HIV.
  - Iatrogenic: e.g. following posterior colporrhaphy.

Faecal fistulas in children present with the child leaking stool in the vagina. There are two main causes:

- (a) Fistulas associated with HIV originate from anorectal abscesses. Usually these are low and are often ano-vaginal fistulas. It is better to avoid surgery initially and treat with anti-retrovirals as some may heal without surgery. If they fail to heal, surgical management may be necessary.
- (b) Check for an undiagnosed imperforate or ectopic anus with a RVF.

#### APPROACH TO REPAIR/ STAGED REPAIR OF VVF + RVF

The VVF and RVF can be repaired at the same time or a staged repair can be considered.


- (a) *RVF first*: A staged repair usually means doing the RVF repair first. The advantages of staged repair are:
  - It will prevent fecal contamination especially when no colostomy is present. If the RVF repair breaks down, it will not negatively impact the healing of the VVF (such as if they were repaired at the same time). For these reasons the staged repair helps avoid a colostomy (see below).
  - It means you can focus fully on one fistula without thinking about the other one and so do a better repair.
  - Blood loss should be less. When doing a combined repair, blood loss can be considerable.
  - It avoids putting tension on the tissues used for the VVF repair.

A staged repair is especially important for the larger (RVF) cases. If the RVF is small, some surgeons feel happy to do them in the same surgery although a staged repair is still a safer option.

- (b) *VVF first or repair both at the same time*:

- In case of a circumferential RVF where a colostomy will be required (see below), you can first do a colostomy, then deal with the VVF and later do a (vaginal or abdominal or a combined) repair of the RVF.

- If there is rupture of the anal sphincter then the VVF may be done first for access reasons. However, it is a good idea to close the rectum at the same time to avoid stool entering the vagina after the surgery.
- If the RVF is only diagnosed while you are doing a VVF repair, then it makes sense to repair both during the same surgery.

	Irrespective of which approach is used, combined VVF and RVF are often difficult operations and are best left for an experienced surgeon.
---	---



### TIMING OF REPAIR

Similar principles apply to RVFs as with VVFs. They can be repaired when they are clean. However, very small RVFs (<1cm) often close spontaneously so it is worth waiting 3-4 months post-injury.

### WHEN IS A COLOSTOMY ADVISABLE FOR RVF REPAIR?

There are two main reasons why a colostomy may be performed:

- I. To protect from fecal peritonitis, pelvic abscess and sepsis if an anastomotic leak occurs.
- II. To decrease the incidence of anastomotic leakage. The consensus is that colostomies do help in the healing of RVFs. However, most RVFs can be repaired without colostomies. There are times that they should be considered although there are no hard rules for this. Much depends on the experience of the surgeon and the type of RVF. It is more common to regret not doing a colostomy than doing one unnecessarily.

<i>Absolute</i>	The RVF is due to radiotherapy which results in poor healing (see section 3.9).
<i>Most surgeons would do:</i>	For all circumferential rectal repairs irrespective of whether it is performed abdominally or vaginally (see section 7.2 below). This applies especially if the anastomosis is within the peritoneal cavity because if it breaks down it is likely to leak into the peritoneal cavity.
<i>Relative indications:</i>	<p>A colostomy may be required if (it is often a combination of factors rather than one alone):</p> <ul style="list-style-type: none"> <li>• <i>Surgery</i> in the past i.e. previous failed repair especially if multiple failed repairs.</li> <li>• <i>Scarring</i>: Usually difficult cases have a lot of scarring around them with poor mobility.</li> <li>• <i>Size</i>: A large RVF especially it required extensive dissection as these are more likely to leak.</li> <li>• <i>Site</i>: If the fistula is to be repaired abdominally: some surgeons feel happy to repair these without a colostomy if there is good bowel preparation, and it can be closed without tension.</li> <li>• Poor general condition of the patient.</li> <li>• If the RVF is present with a difficult VVF (see <i>Approach to repair</i> above): <ul style="list-style-type: none"> <li>➢ A bladder fistula often breaks down if covered with stool during recovery.</li> <li>➢ If the VVF or RVF requires a large skin flap or a Gracilis flap, you do not want to risk a breakdown.</li> </ul> </li> </ul>
<i>Decision made at surgery</i>	<p>If the bowel has been well prepared pre-operatively, you can leave the decision to do a colostomy until the time of the repair. If you can get a good two-layer closure, then a colostomy is not usually needed. Consider a colostomy if:</p> <ul style="list-style-type: none"> <li>• You find the tissues are not of good quality (e.g. friable or scarred) or there have been technical problems during the surgery and you are worried it may not heal if tested with stool passing through. The main problem with waiting to do the colostomy at the time of surgery is the tendency to avoid doing another procedure at the end of what may have been a long operation.</li> <li>• If there is a leak of air when the anastomosis is tested (see section 7.4).</li> </ul>
<i>Decision made later</i>	If the repair leaks, it is often a good idea to do a colostomy for two reasons: (a) It may still help the RVF to heal. (b) It is likely that a colostomy will be needed for any further repairs. However, see below "Post-operative Care after RVF repair".
 <b>Tip!</b>	To avoid a colostomy: (a) Do a staged repair. (b) Ensure good (oral) bowel preparation. (c) Aim for a two-layer closure.
	It is important to consider how easy it will be for the patient to get the colostomy closed later so that the patient is not left with a colostomy for a long time.

### MAKING A COLOSTOMY:

If a colostomy is performed before the repair, it is best to do it at least three days before any RVF repair so that the patient has recovered from the surgery.

*Sigmoid loop colostomy*: In most cases, it can be done through a small incision midway between the umbilicus and the anterior superior iliac spine.

- The sigmoid colon is brought out through this incision and fixed. Make sure you can see the taenia coli. The only disadvantage of doing it this way is that you cannot be certain which is the proximal and which is the distal end.
- The stoma site should be as wide as necessary to deliver the bowel loop extra-abdominally without force (3-4 cm).
- To help prevent prolapse of the colostomy: fix the serosa of the bowel to the fascia with two sutures on each side of the fascial incision.
- After performing the colostomy, it is a good idea to wash out the distal end of the sigmoid and rectum through the colostomy. This can be done using a large Foley catheter or suction tubing. If the saline does not appear through the rectum after several syringes of saline, you may be irrigating the proximal end. Also, irrigate from the anus and vagina so that both the rectum and vagina are clean.


*Transverse colostomy:* has the advantage of not interfering with the recto-sigmoid thus facilitating the dissection and closure of a high RVF via the abdominal route. The site is approximately midway between the umbilicus and the costal margin so should be 2-4 finger-breadths below the costal margin.


**Before closing a colostomy:** It frequently happens that colostomies are closed even though the RVF has not healed. After repair of the RVF, complete healing should be shown by a combination of (a) injecting dye down the distal loop of the loop colostomy with a clean swab in the vagina (b) a rectal examination. Do not rely on dye injected through the anus as this can give a false negative test especially with high RVFs. A good option is to do all this under anaesthesia, with the patient prepared for closure of colostomy at the same time provided that the dye test is negative. However, make sure it was a loop-colostomy that was performed and not an end-colostomy before doing the dye test and before any surgery. Also, exclude any stenosis in the rectum by performing a rectal examination and palpating high up.

### BOWEL PREPARATION FOR RVF REPAIR

There is no perfect way of ensuring the bowel is clean for surgery. The oral regimes are the best. With enemas, there may be problems passing a tube due to rectal stenosis, or the fistula could allow the tube to enter the vagina. A combination of the following is used:

- Diet:* For 3 days pre-operatively a fluid diet (e.g. soup for 1-3 days followed by clear fluids the next day e.g. tea, juices) is given.
- Oral preparation* works well to ensure more complete emptying of the bowel. If preparations such as Picolax are not available, then oral normal saline can be given by mixing 9 grams of salt in a litre of water. This can be made approximately by adding six level tablespoons of salt in 10.5 litres of water at room temperature. The patient takes this solution the day before surgery until the fluid coming out rectally is clear. Ideally, she should take it all but at least 6 litres should be taken. The fluid intake should be completed by 1400 hours the day prior to surgery and no enemas are required.
- Enemas* should be given daily for 3 days with the last one at least 12 hours before surgery, otherwise the enema will work during the operation. An easily available option is a saline enema: one teaspoon or 5 ml of salt is dissolved in 1 litre of water. Initially, use 100 ml of warm water to dissolve the salt and then add the rest so the water is close to body temperature. The patient holds the enema as long as she can. Another option is a phosphate enema.
- May give an oral laxative such as Bisacodyl for 3-4 days.

 **Tip!** If necessary during surgery, formed stool can be blocked by placing a pack high up the rectum. Attach a string on it for easy recovery at the end of the procedure.

	<ul style="list-style-type: none"> <li>• Make sure the patient does not become dehydrated during the bowel preparation so hydrate well to avoid this. This is especially important when spinal anaesthesia is used during surgery.</li> <li>• It is the surgeon's responsibility to ensure the bowel preparation is performed properly. Therefore check the patient the day before surgery to ensure the preparation is being performed properly. If in the theatre it is obvious that preparation was not adequate, it is better to postpone.</li> </ul>
---	---

It is useful to make a distinction between:

- *3- stage RVF repair* i.e. (1) defunctioning colostomy (2) RVF repair (3) closure of the colostomy.
- *2- stage RVF repair:* this is a better option provided that full bowel preparation is given first. (1) RVF repair and protective colostomy performed in the same session (2) closure of the colostomy.
- *1- stage RVF repair* i.e. primary closure of RVF after adequate bowel preparation i.e. no colostomy.

**(7.1A) RVF: TRANS-VAGINAL REPAIR**

The trans-vaginal approach is preferred for those fistulas proximal to the anal sphincter. This is the case with most obstetric RVFs.

**(1) EXPOSURE**

**Table:** With a high fistula, head down tilt may be needed. With a low fistula, a head-up tilt is needed. In between, the table should be horizontal.

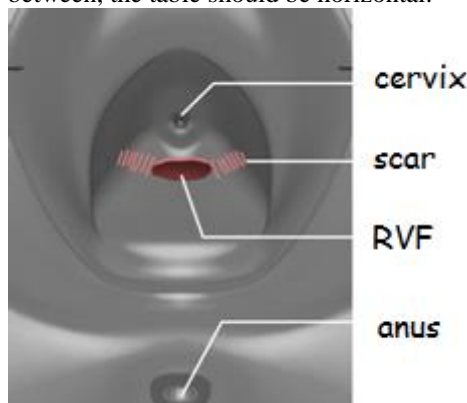


Fig. 7.1a: RVF with surrounding scar.

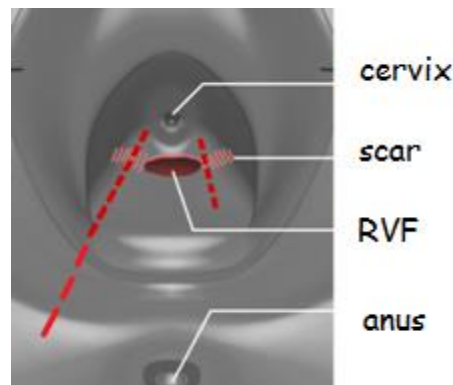


Fig. 7.1b: The line on the patient's right is the episiotomy. The line on the left is the incision for the scar only. Note that both pass along the edge of RVF.

**Incisions to improve exposure:**

- (a) *Scar incision (confined within vagina):* Very often the RVF is in the centre of a band of scar (Fig. 7.1a) which has to be cut laterally on both sides to allow visualization of the RVF. If no episiotomy has been done and there is a lot of scar tissue in the vagina, cut this laterally at 5 and 7 o'clock which is usually just lateral to the fistula. It is a good idea to use cautery to make these incisions to minimize bleeding. A small retractor on the anterior vagina helps visualization. Beware of creating another rectal injury when taking down these scar bands laterally.
- (b) *Episiotomy (extends onto perineum):* It may be helpful to do an episiotomy extending to the edge of the RVF to improve access. This can come as a distal extension of the incision you made to cut the scar bands. Decide which side is best depending on the position of the RVF. Occasionally you may need to do bilateral episiotomies for an RVF repair.

**! Tip!** The important point when cutting scar or doing an episiotomy is to aim the incision just along the lateral edge of the RVF as shown in Fig. 7.1b.

**! Tip!** Occasionally converting an RVF to a 4<sup>th</sup> degree tear can be useful if access is very difficult due to vaginal scarring. This should really only be done if the sphincter is also torn. If the sphincter is intact, you should repair these fistulas without converting to a 4<sup>th</sup> degree tear to avoid any further compromise to the sphincter.

**! Tip!** Some surgeons operate by keeping a left index finger in the rectum for most of the operation to help exposure of the fistula by bringing the anterior rectal wall forward (Fig. 7.1d +e). This is more useful for low fistulas. Your assistant would have to tie the knots for you. There are two cautions with this technique:

- Beware of needle stick injury when doing this.
- Try not to touch the open wound with your contaminated finger.

**! Tip!** Some surgeons use a Foley catheter to apply traction to the fistula which helps with dissection (see Fig. 7.1f). It is unusual to be able to do this for most obstetric RVFs.

**Speculum:**

- It may help to hold a Sims speculum or a small retractor against the anterior vaginal wall for visualization (Fig. 7.1c).
- A Sims speculum on the posterior wall is useful for high fistulas. It may be possible to use a weighted speculum.
- The position of the speculum can be varied during the operation to give the best exposure; initially it may be held against the anterior wall and later against the posterior wall. Manipulate it to see which

position gives the best exposure. It may be necessary to use one anteriorly and another one posteriorly (without obscuring the RVF).

- In some cases, it may not be possible to insert any specula; there will only be enough room to apply Allis forceps to the edges of the vagina (Fig. 7.1c + d). Pulling down on these helps expose the fistula.
- A side-wall retractor can also be useful laterally especially when stitching the lateral angles.

**Tip!** The suction tip is often the best retractor as it is long and takes up little room when you are trying to expose the apex of the RVF.

**Tip!** For high fistulas, firm tubing (e.g. endotracheal tube) or a large dilator can be placed up the anus or through the fistula into the rectum to help in identifying the lumen during dissection.

**Tip!** With high fistulas, holding the cervix with a long Allis forceps, and pulling it up is very useful.

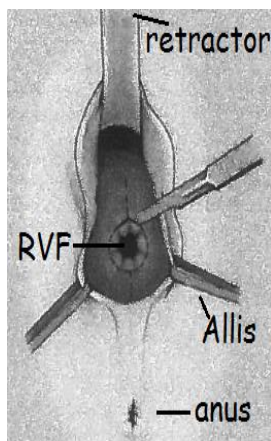


Fig. 7.1c: For a low fistula, place two Allis forceps at 5 and 7 o'clock at the entrance to the vagina.

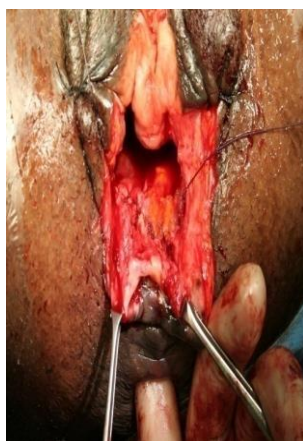

Fig. 7.1d: Shows the use of two Allis forceps, and surgeon keeping a finger in the rectum during repair for exposure.

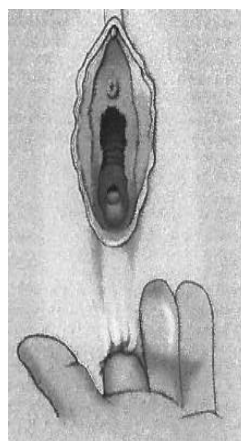


Fig. 7.1e: Shows the left index finger inserted into rectum to expose the fistula.

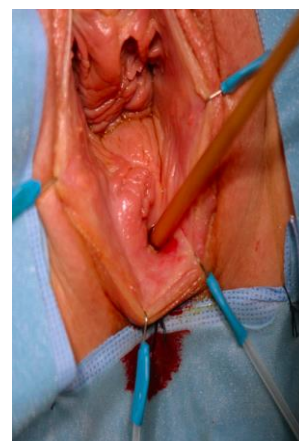

Fig. 7.1f: Shows the use of a Foley catheter to apply gentle traction to the fistula tract which helps in exposure.

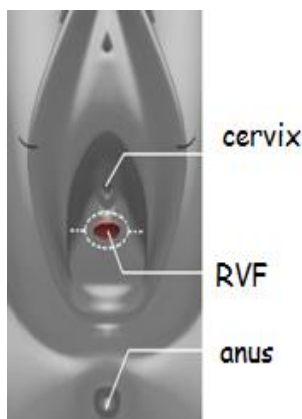


Fig. 7.2 a +b: Shows the incision to make around the fistula. (Courtesy of Grace Chen).

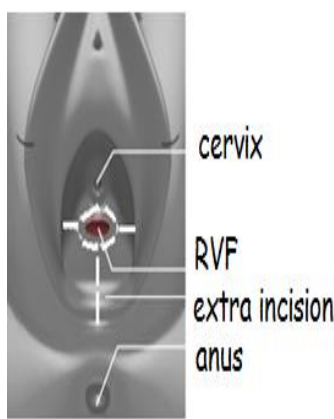
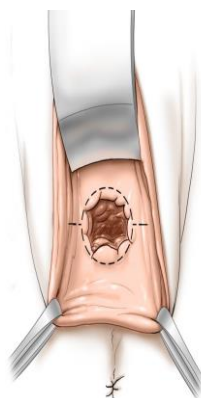


Fig. 7.2c: In a high or mid-vaginal RVF, an extra incision can be made distally to aid distal dissection.

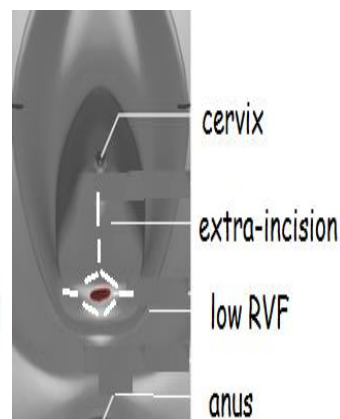


Fig. 7.2d: In a low RVF, an extra incision can be made proximally.

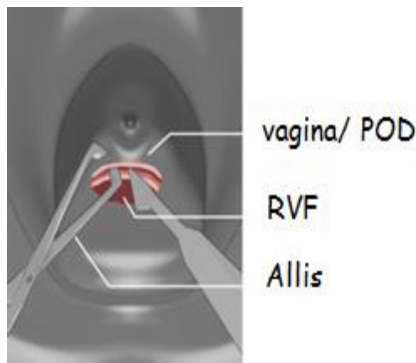
## (2) INITIAL INCISION

- Infiltrate diluted adrenaline solution as for VVF repair (see chapter 1).
- The incision is similar to that used for a VVF with a lateral extension on either side (see Fig 7.2a + b). It may also help to make a midline extension as shown in Fig. 7.2 c + d. In this case, two flaps are formed and these can be retracted back with sutures.

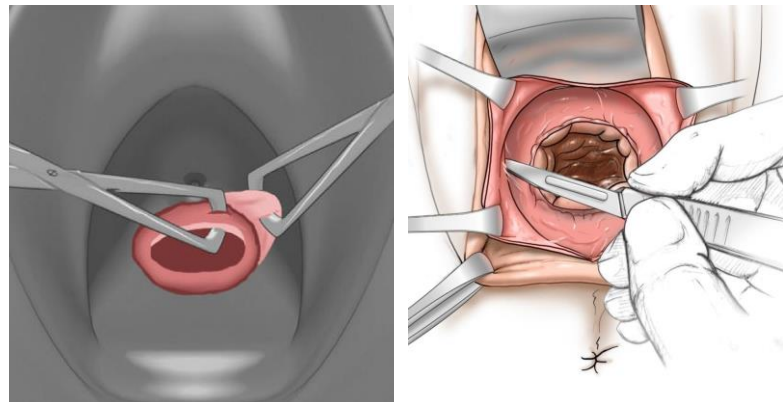
**Tip!** Occasionally the rectal mucosa will prolapse down through the fistula which makes exposure difficult. A useful tip is to put a small swab up the rectum to push the mucosa up.

**(3) DISSECTION**

- (a) Proximal:** Start dissection proximally (at the top), where there is more mobility. Grasp the edge of the rectum (or vagina in difficult cases) with an Allis. Then with a knife incise the vagina proximal to this (Fig. 7.3). Once the incision is made, grasp the vaginal edge with a second Allis forceps. Dissect the vagina off the rectum, staying close to the vaginal skin as you do so. Use scissors for this.



*Fig. 7.3: To start the proximal incision hold the rectum or the vagina with an Allis forceps to provide tension as you make the initial incision. POD = Pouch of Douglas*



*Fig. 7.4: Diagram on left shows the use of Allis forceps to develop tension to help find the tissue plane. The diagram on the right shows the lateral dissection being performed while this tension is maintained.*

*If the pouch of Douglas opens:* As you mobilize the vagina proximally, the pouch of Douglas often opens. This does not matter and it will help with mobilization. In fact, with more proximal fistulas, it is a good idea to deliberately open the pouch. Often there is a small amount of fluid in the pouch, which helps identify it.

- If only a small opening is made, it is worthwhile opening it fully to visualize the proximal rectum better.
- If the small bowel prolapses, obscuring the field of view, put a (vaginal) pack in to keep the bowel out of the way and clip the end of it to the drapes. The pack will be in the peritoneal cavity. Also, increase the head-down tilt of the table if possible.
- You can put a Sims speculum into the pouch to retract anteriorly as this will give a good view.
- If there is faecal spillage from a poorly prepared bowel it might contaminate the peritoneal cavity.

**! Tip!** If it is difficult to close the peritoneum, leaving it open will not usually cause any problems provided there is no spillage of faeces i.e. the peritoneum opening is incorporated into the vaginal closure.

- (b) Lateral:** Once the proximal dissection is done, dissect laterally on each side while pulling the rectum medially. Grasp the vaginal skin on one side and the rectum on the other side with Allis forceps and cut between them (as shown in Fig. 7.4). Work proximally and distally on the lateral side to separate the vagina and rectum. The angles of the fistula may have to be freed from the pelvic side-wall where there is often a lot of scarring. **CAUTION!** Be careful of bleeding here (see below).

- (c) Distal:** The distal flap is usually more fixed and therefore more difficult to mobilize. There are two tips to help with this:

- Make an extra incision in the midline from the fistula distally (Fig.7.2c) and then separate the vagina off the rectum.
- Put your finger or a dilator in the rectum for exposure.
- Once dissected, the distal vaginal flap(s) can be stitched back to the skin for exposure.

**! Tip!** In difficult cases, it may help to do dissection at the distal end first for exposure, before doing the proximal and lateral dissections. In this way, you can follow the rectal edge around and proximally.

**! Top Tip!** When it is difficult to see the outline of the rectal defect, place Allis forceps all around the rectal edges. The sidewall retractor placed laterally can also help in exposure.

**! Tip!** A large Hegar dilator (inserted through the anus) is a very useful instrument to check that the lumen of the rectum is patent (proximal and distal to the fistula site) and confirms that the tissues you are holding are the fistula edges.

#### (4) CLOSURE OF RECTUM

Trim the fistula edges until they are soft. It may help to hold the proximal and distal edges of the rectum with Allis forceps. Normally the fistula is closed in a transverse direction (Fig. 7.5). This is less likely to cause narrowing and usually creates the least tension, as there is less mobility laterally due to scarring. However, it may be necessary to close it longitudinally or obliquely.

- Use interrupted absorbable sutures. Always start the repair at each angle, avoiding the mucosa. It is more important to get the mucosa to invert rather than trying to pick up the mucosa. This is done by picking up a sero-muscular layer with the needle and starting 2-3 mm from the edge (Fig. 7.5).

**!Tip!** Leave the angle sutures (short-end) on an artery forceps and leave them extra-long or on a straight forceps so they are easily identified later.

- The red rectal edges are inverted by pushing the Allis or pickups/ dissecting forceps towards the rectal lumen as you tie the knot (Fig. 7.5). There should be no visible red mucosa if the first layer is closed properly.
- It may help to place a finger or a dilator into the rectum to push the distal edges forward as you place the sutures.
- It is often technically easier to place the proximal bites transversely (Fig. 7.6).
- As you suture towards the midline, it is often better to place the final three sutures but do not tie them until they are all in place.
- The main use of a backhand grip in RVF repairs is shown in Fig. 7.7a.
- If there is a discrepancy in size between the proximal and distal parts of the rectum, either:
  - Place the stitches closer together in the narrower part and
  - Place the stitches transversely in the wider end and vertically in the narrow end.
  - In these cases, check for strictures during the repair. If a stricture is developing, consider incising the narrow (usually distal) end similar to Fig. 7.11c.

➤ A rectal examination is done after placement of all stitches to test that the repair is complete.

**One versus two-layer closure:** Most fistula surgeons aim for a two-layer with interrupted sutures (Fig. 7.7b) closure. The second layer is made from: (a) Proximally: Rectum or peritoneum. (b) Distally: Rectum or any distal tissues. Occasionally the second layer can be difficult and one good layer without tension has to be accepted. In this situation, consider an intermediate layer. If there is a colostomy, then there is no point in doing a second layer.

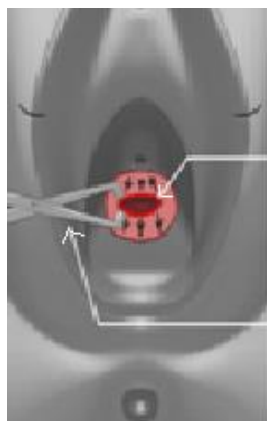


Fig. 7.5: Closure of the rectum. Sometimes it helps to hold the edges with Allis (arrow) or dissecting forceps to help invert the rectal mucosa (arrow).

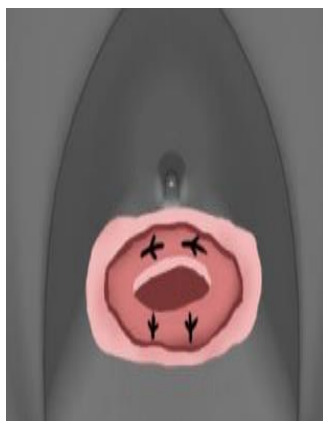


Fig. 7.6: It is often technically easier to place the proximal bites transversely.

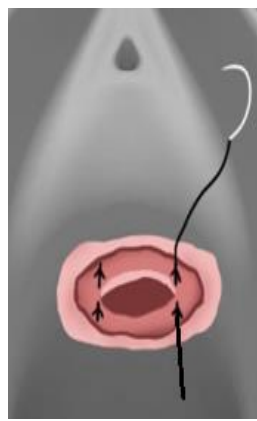


Fig. 7.7a: In this case, the sutures are placed in the distal end first with a backhand grip.

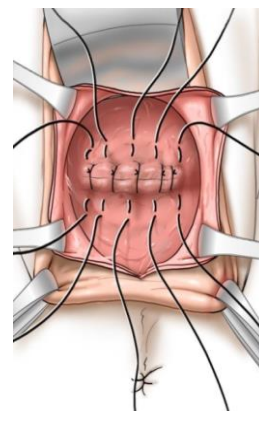


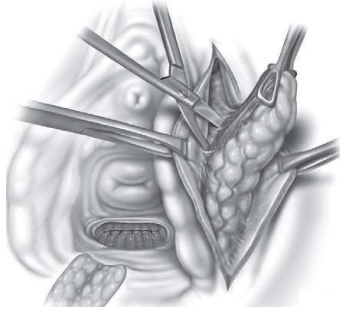
Fig. 7.7b: Shows a second layer of sutures inserted for rectum but not yet tied.

#### (5) INTERMEDIATE LAYER

While not commonly used in most RVF repairs, this can be considered especially in recurrent, very scarred or post-radiotherapy RVFs. (This is independent of any decision to do a colostomy.) It may also be considered in cases where only a one-layer closure of the rectum is possible. The options are:

- For mid and distal vagina fistulas: suture a sheet of levator ani (pubo-coccygeus) muscle in front of the rectal repair (see Fig. 7.8b). This can be mobilized on one or both sides as in VVF repair and applied as a sling (bilateral) or a patch (unilateral). The muscle is found laterally on each side under the vaginal skin.

- Martius flap (see Fig. 7.8a): It is important not to divide the pedicle graft until it has been determined that the length that has been developed is adequate so measure using a piece of drain or gauze.



- Gracilis flap (see section 8.4): I have used this on several occasions for obstetric RVFs where it was unlikely that they would have healed otherwise. The important tip is to leave the angle sutures (both ends of each) long to be used to fix the graft in place. Fix the muscle on the side closest to the graft first over the fistula. Then fix the far side.
- Use a Singapore flap (see section 8.1) or only the fat/ fascia of a Singapore flap.
- Human Amniotic Membrane is also used as an intermediate layer.

Fig. 7.8a: Shows a Martius graft being used as an intermediate layer in a low RVF.

## (6) CLOSURE OF THE VAGINAL WALL

There is usually a significant gap between the proximal and distal edges of the vagina. However, the vaginal edges are already mobilized from the initial dissection and can usually be brought together easily.

- Hold the proximal and distal edges with Allis forceps.
- Use a horizontal mattress suture (Fig. 7.9a). Take the first bite proximally (1), then down to the distal edge (2 and 3) and go back proximally (4) and tie.
- Start at the angles first and do the central part last. Using this method, often large defects can be closed.
- If closing the vagina is likely to result in stenosis, there are two options:
  - i. *Kees neovagina* (see chapter 8): For high and mid-vaginal RVFs with the pouch of Douglas open, the peritoneum is used to form the new vagina. It is much safer to do this at the same time as the RVF repair rather than later as there is little or no risk of rectal injury.
  - ii. Do a skin flap (section 8.1).

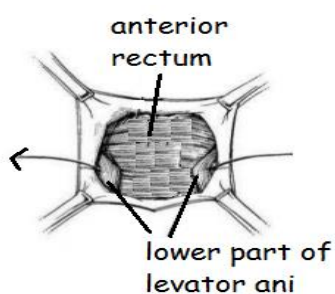


Fig. 7.8b: Shows the levator ani about to be approximated.

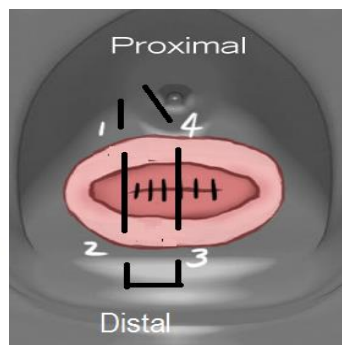


Fig. 7.9a: Vaginal closure with mattress suture.

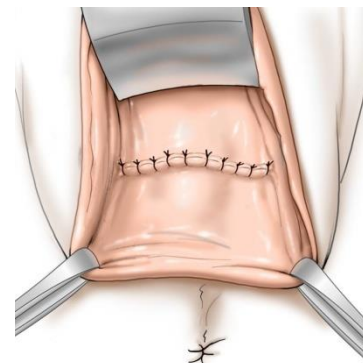


Fig. 7.9b: Shows the vagina now closed. (Courtesy G Chen)

## PROBLEMS DURING TRANS-VAGINAL REPAIR

### (1) The difficult RVF

- If the fistula appears to be going around to the lateral rectum, place Allis forceps all around to see the limits of the defect.
- The sidewall retractor can be useful laterally especially when stitching the angles.
- If the defect appears to only come together longitudinally, try to close it more obliquely to avoid narrowing the bowel.

(2) **If the RVF is very lateral:** a large episiotomy on the affected side can help greatly. Then, similar to a lateral recurrent VVF, the trick is to free the lateral border of the fistula so that it is mobilized medially.

(3) **If heavy bleeding occurs** (see also page 34: Bleeding during fistula surgery):

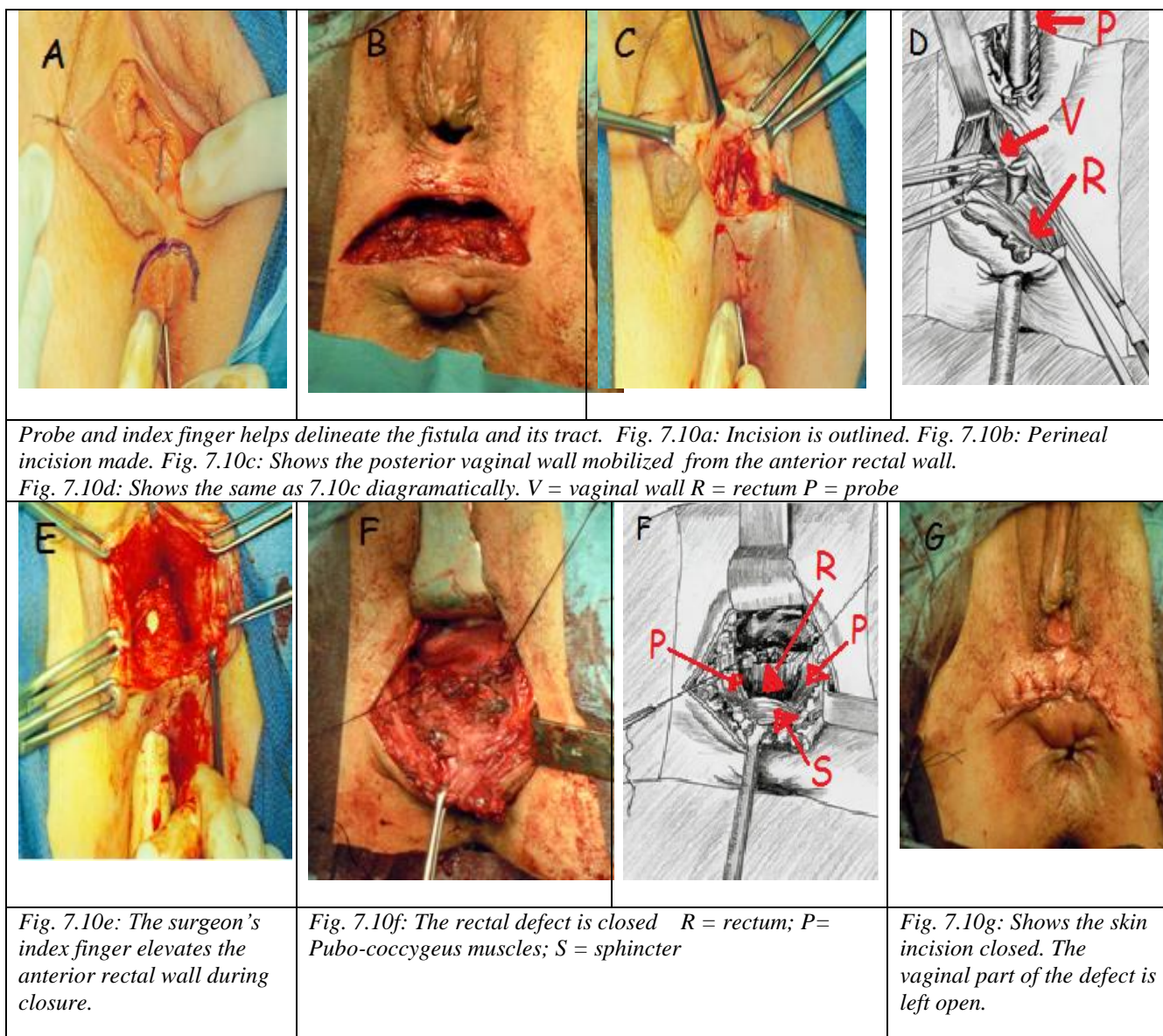
This may occur when the fistula is stuck laterally and you have to dissect it free. You may hit a large vessel which is the terminal branch of the middle rectal artery.

- Apply a clamp and suture the vessel, or cauterize using low voltage e.g. 20 watts. If you use high voltage, it only cauterizes the superficial tissue, as it carbonizes the superficial layer which then can no longer conduct the voltage. It means that you have to press for longer for the voltage to go deeper.
- If you fail to stop the bleeding:
  - Pack (may soak in diluted adrenaline 1:250,000) and apply pressure for 5 minutes.



- Leave the clamp on for 30 minutes. The operation can usually proceed with the clamp on.
  - If available, haemostatic agents e.g. Surgicel or Floseal can be applied to stop oozing.
  - On one occasion during vaginal repair when it was difficult to stop lateral bleeding, I packed the bleeding area laterally, repaired the RVF and took the pack out vaginally the next day. Part of the vagina was left open to allow this.
  - If heavy bleeding occurs posteriorly over the sacrum, a few stitches with a strong needle may work. If not, abdominal control of the sacral veins (often only by packing or the use of thumb-nails as it can be difficult to see anything) may become necessary and the repair may have to be completed from above.
- (4) **If a second hole develops during dissection:** this is more likely to be proximal than distal to the fistula. It is usually easiest to close this hole together with the fistula (similar to Fig. 3.13b) although separate closure (similar to Fig. 3.13c) is an option if the distance between the two holes is far.

**(7.1B) RVF: TRANS-PERINEAL APPROACH**



In addition to the vaginal and abdominal approach, RVFs can be repaired through a trans-perineal approach. The location of the fistula is the main determinant. The trans-vaginal approach is good for those fistulas more proximal from the anal sphincters. For more distal fistulas, the trans-perineal approach allows better access. The trans-perineal approach is most often used in partial breakdown of 4<sup>th</sup> degree tears and non-obstetric fistulas. The advantages are: (a) It avoids cutting the sphincter for access and so preserves any intact internal and external anal sphincter. (b) If the sphincter is torn, it allows good access to repair it. Note: In the case of a very

small and distal RVF which only causes occasional flatus per vagina, there is the option not to operate at all, as perineal surgery might cause iatrogenic anal sphincter or pudendal nerve damage. *Method:*

- Pass a probe through the fistula. Make an incision in the vagina around the RVF if possible.
- Make a transverse or inverted U incision across the perineal body above the anal sphincter as shown in Fig. 7.10 a + b. This incision can be made at the level of the posterior fourchette i.e. junction of the vagina and the perineal body, or lower.
- The incision is deepened until you reach the probe. Then pull the probe back so that it is only just coming through the rectum.
- Separate the vagina from the anus and rectum proximal to the RVF which is now exposed.
- Dissection is extended laterally and proximally around the fistula between the anterior rectal wall and posterior vaginal wall. Stitch the vaginal wall back with two sutures.
- Excise any scar tissue from the fistulous opening at the rectal end and repair the rectal wall transversely with interrupted sutures to invert the rectal mucosa. It is easiest to do this initially while the probe is still in the rectal opening. A second layer may be placed.
- Approximate any recto-vaginal fascia. Approximate the pubo-coccygeus muscles across the midline.

### (7.2) RVF: TRANS-VAGINAL REPAIR: CIRCUMFERENTIAL DEFECTS

Circumferential defects occur in the rectum but are not as obvious as in the bladder. There are two clues:

- Often the lateral angles of the fistula seem to go very far around posteriorly and there is usually a lot of scar tissue in this area.
- When there is marked stenosis, suspect that the defect is circumferential.

The main reasons for doing circumferential dissection is either to help mobilization of the two ends or to resect the stenotic area. The stenotic area is the scarred tissue that bridges the gap between the two parts of the rectum.

- If you cut across the narrow bridge of tissue posteriorly (Fig. 7.11 a) and dissect under the proximal rectum, this allows you to bring the proximal rectum down. The distal part of the rectum also has to be mobilized to a more limited degree.
- After dissection, close the posterior layer, followed by the anterior layer as in any bowel anastomosis. It is better to use interrupted sutures which are mainly placed in the seromuscular layer. The sutures are tied as they are placed.

*Posterior wall:* Start with a suture posteriorly in the midline placed from inside the lumen of the rectum (Fig. 7.11b) so the knots end up inside the lumen. For exposure, it is easier to work either first to the left and then to the right or the other way around. As you reach the lateral edges, the sutures are placed from outside the rectal wall.

*Anterior wall:* As you approach the midline anteriorly, it may be better to place several sutures but only tie them once all are placed.

- If not done previously, perform a colostomy.

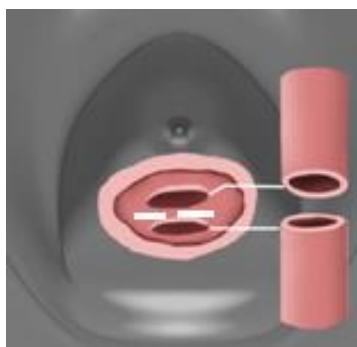


Fig. 7.11a: The white line represents the incision to be made between the proximal and distal ends of a circumferential defect.

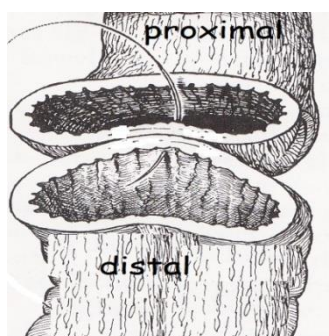


Fig. 7.11b: Closure after circumferential dissection begins in the midline posteriorly as shown.

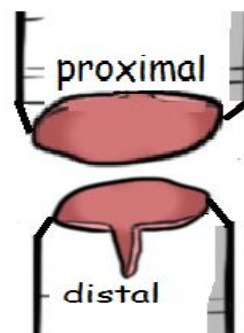


Fig. 7.11c: If there is a large discrepancy in the two ends, the narrower end (distal here) can be incised to enlarge it as shown.

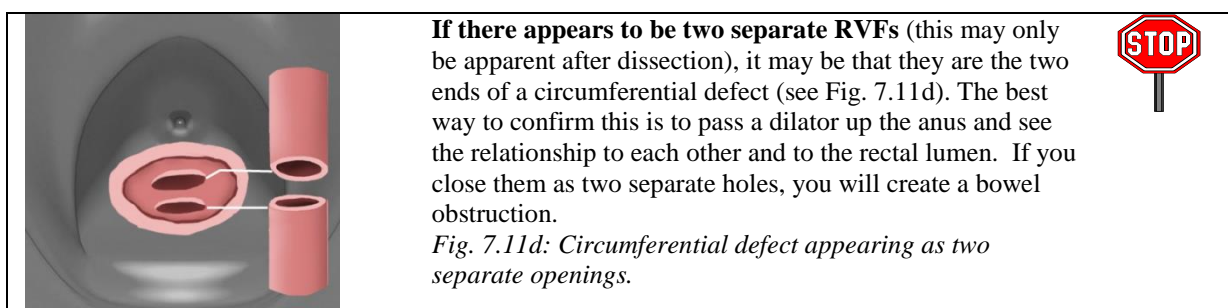
**⚠ Top Tip!** If there is a discrepancy in the size of the two ends with the distal end narrower, take the bites wider apart or take more horizontal bites on the wider end. If there is still a discrepancy and there is a tendency to stenosis as you close the defect, then an incision on the anterior wall of the narrow end (Fig. 7.11c) will help overcome both of these problems.

**! Tip!** On the right anterior wall, you may find it easier to suture from the distal end to the proximal with the needle as a backhand.

**RECTAL STRICTURE:** It is important to look for the presence of a rectal stricture due to scarred tissue surrounding the defect. Over 50% of high RVFs have strictures and if you do not do something about the stricture, the RVF will not heal. Mid-vaginal RVFs do not usually have a stricture. The general rule when dealing with strictures is that if you can pass your finger through the stricture, stool will get through. There are two ways of dealing with strictures:

- (i) As they usually occur with circumferential defects, dissecting circumferentially will excise the stricture.
- (ii) If a stricture is found later or you are not doing circumferential dissection, disrupt the stricture digitally or with a Hegar dilator. Aim to get two fingers through the stricture to disrupt the scar as you need to get the diameter of the rectum to about 2.5 cm.

In the past, cutting scar tissue posteriorly at the site of the stricture (less likely to enter the peritoneal cavity than cutting anteriorly) has been advocated. However, it is not advised as there is still a risk of peritoneal entry especially if the stricture is high, and subsequent peritonitis may result which can be difficult to recognize.



### (7.3) RVF: ABDOMINAL REPAIR

*Indications:*

- If the fistula is not visible vaginally.
- If the distal end is visible vaginally but the proximal end can only be accessed abdominally. In this case, start the dissection of the distal end vaginally and then complete it abdominally.

**! Tip!** If the proximal end of a circumferential defect is not easy to see, it is often found in scar tissue in the midline. It is therefore worth doing some dissection vaginally as this may avoid a laparotomy if you find the proximal end.

*Positioning for abdominal repair:* Place the patient in low-lithotomy so you may access the perineum/ rectum from below as well as from above. This position also allows a second assistant to stand between the legs. Irrigate the rectum with Betadine solution to allow access to the rectum during the operation e.g. to do rectal examinations or pass a large Hegar dilator in difficult cases.

**! Tip!** It helps to place a tube (e.g. large suction tube or a Foley catheter with the balloon inflated) into the rectum as this will help you identify when you enter the rectum during dissection. The Foley catheter can also be used to do an air insufflation test later (see below).

*Exposure:* Pull up on the uterus with a fundal suture as shown in Fig. 7.12A. A good headlight for visualization is very useful in this space.

**! Top Tip!** A useful trick to keep traction on the uterus is to place the artery forceps holding the fundal suture under traction and then place a towel clip through this to attach it to the drapes.

*Dissection:* The rectum is sharply dissected off the posterior vaginal wall.

- Start dissection on either side of the rectum by opening the visceral peritoneum. Identify the ureters and work down on either side to below the level of the fistula.
- Next cut across the recto-vaginal/ uterine fold of peritoneum.
- It may help to mobilize behind the rectum to free it to some degree although more full mobilization is only possible after it is freed from the vagina anteriorly (distally).
- The rectum is then opened with scissors where it is stuck to the vagina i.e. at the fistula site. Initially, your left hand stretches the rectum proximally while your right hand cuts. Then your left index finger can be used to feel the remaining tissue to be cut (Fig. 7.12B).

- Mobilize and trim the edges. Check with your finger in order to ensure that there is only one hole.

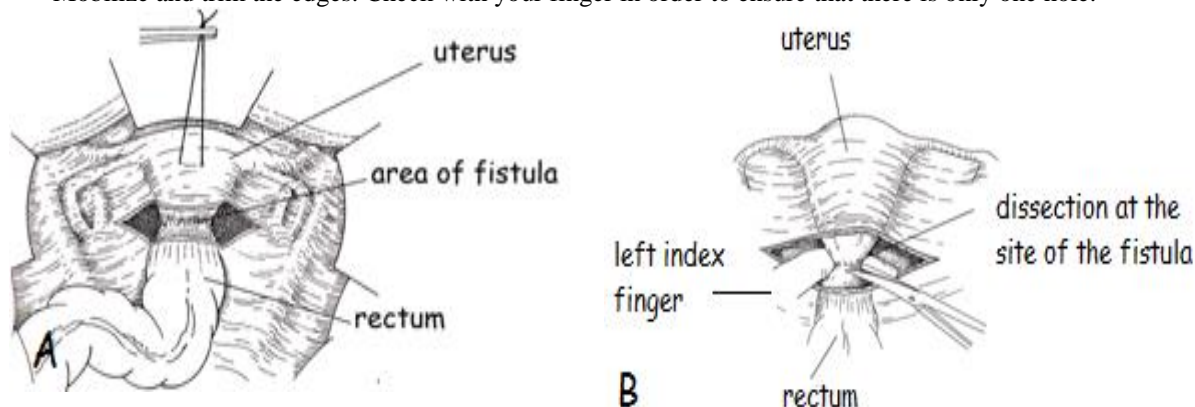


Fig. 7.12: This is the view looking down into the pelvis from above at laparotomy. (A) Fundal suture on uterus for traction, and visceral peritoneum open (B) dissection of the fistula from the vagina. (From Camey M)

**Repair of rectum:** The proximal and distal edges are held with Allis forceps. Suture the edges together with interrupted stitches (Fig. 7.13a).

- Start at each angle laterally and work towards the centre. Often one edge is wider so watch as you suture in case you need to take bites further apart or place them horizontally on the wider edge.
- Take full thickness or only sero-mucular bites
- One layer is sufficient as the aim is to approximate the edges rather than water-tight closure.
- A colostomy should be performed if not done previously. Some surgeons would be happy not to do a colostomy if they have achieved tension free closure, there is no stool contamination during the operation and the air insufflation test is negative (see below).

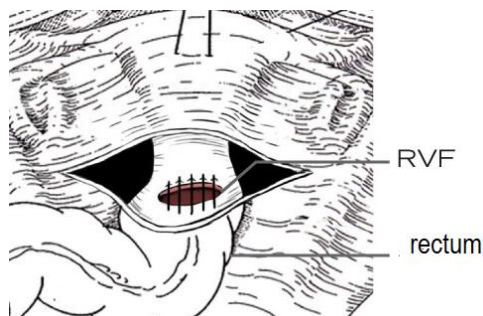


Fig 7.13a: Shows the fistula being closed with a single layer of interrupted sutures. (Adapted from *les Fistules Obstetricales* by Camey M.)

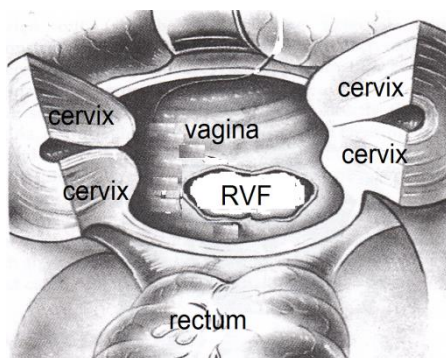


Fig. 7.13b: Shows access to the fistula by splitting the cervix. The fistula is approached anteriorly through the vaginal vault.

**If access is difficult** due to extreme fibrosis and scarring so that the cervix and vaginal vault are fixed to the sacral promontory, then the usual posterior approach via the pouch of Douglas between the rectum and the vagina is not possible. Instead, an anterior approach is used. First, perform a sub-total hysterectomy and then bisect the cervical stump (in an Anterior-Posterior direction). The two halves of the cervix are retracted to either side, exposing the fistula in the posterior fornix (Fig. 7.13b). This approach can also be used if the RVF seems to be very low abdominally so that you cannot access it even though you have failed to access it vaginally. It is an approach that I have found useful on several occasions. *Reference: Recto-vaginal fistulae following difficult labour. Lawson; JProc R Soc Med. 1972 Mar; 65(3):283-6.*

#### (7.4) CIRCUMFERENTIAL RVF DURING ABDOMINAL REPAIR

These cases usually have stenosis of the rectum at the fistula site. After dissection and mobilization of the fistula (and excising any remaining stenosed area), you are left with two ends of the rectum to join together. The technique of low rectal anastomosis is used:

**! Tip!** The distal end of the rectum may retract downwards. Grasp the edges all around with Allis or Babcock forceps to pull it up. If you fail to secure the distal end, you would have to do a pull-through procedure (see below).

**! Tip!** It is vital to ensure that both ends of the bowel are well vascularised and mobile. You may need to mobilize the proximal end, going behind the mesentery and also up to the sigmoid to achieve this.

**! Tip!** If there is already a sigmoid colostomy present, it may be necessary to take it down to allow the proximal end of the bowel to come down into the pelvis. After the repair, it is often easier to place a loop ileostomy in the same site or to do a transverse colostomy.

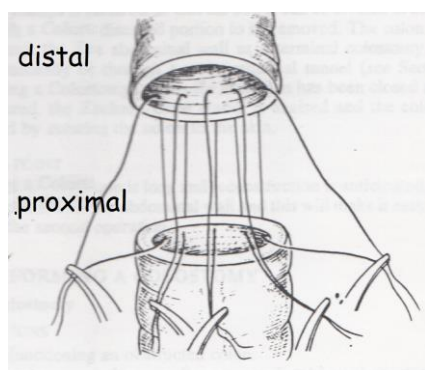


Fig. 7.14a: Closure of a low circumferential defect by abdominal approach. This shows the posterior wall being closed with all the sutures placed but not tied (view from above).

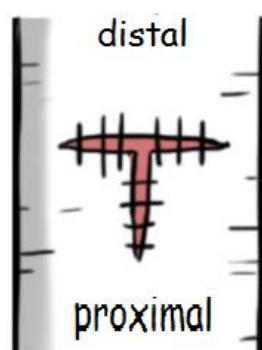


Fig. 7.14b: If the proximal edge is wider, closure of the anterior layer may result in a T-line of closure.

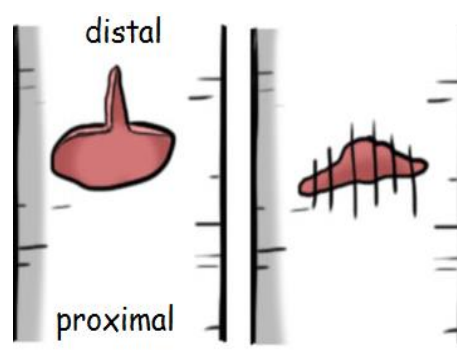


Fig. 7.14c: If the proximal edge is wider, a better option is to widen the distal end by incising the anterior wall as shown on the left.

- (1) Place a **lateral stitch** on each side (3 and 9 o'clock). This is done from out to in and in to out so the knots are outside. These are placed but not tied until you have placed and tied the posterior row.
- (2) **Posterior row:**
  - Usually, start on the right side just medial to the lateral stitch (Fig. 7.14a) and work towards the left side.
  - Place (but do not tie) all the posterior interrupted sutures going through all layers (may avoid the mucosa if you wish). This is done from inside the lumen so the knots end up inside the lumen. Bite first the proximal and then the distal rectum.
  - Retraction on the previous stitch can help place the next stitch.
  - About 9-10 such sutures are placed. Each bite is about 3 mm apart, taking 1 cm of good tissue on each side. Once all these sutures are placed, tie them one by one (starting with the last one inserted) leaving the knots on the mucosal side.


**! Tip!** It is very important to keep the order of the artery forceps correct to avoid sutures becoming tangled. There are 4 ways of doing this:

- (a) The simplest is to place a square of gauze over each artery forceps as it is placed. Then when tying, just remove one gauze at a time to expose the correct artery forceps as you tie each suture.
- (b) Place the rings of the artery forceps into a closed long clamp e.g. Kochers. One assistant is given the job of holding this to make sure the artery forceps do not fall off the clamp. Alternatively, attach the tip of the clamp to the drapes.
- (c) Use clamps in a specific order that you use every time you need to hold sutures before tying e.g. use curved artery, straight artery, large artery, Kocher's etc.
- (d) If available, a Lone Star retractor can be used.


(3) **Anterior row:** First tie the initial lateral stitch on each side.

Place the anterior layer of sutures (interrupted) but tie as you place each one. Work from lateral to medial on each side so that you finish in the midline.

- If standing on the left side, place the sutures from proximal to distal.
- If you (or your assistant) are standing on the right side, it is easier to insert the sutures from distal to proximal.
- As you get towards the centre, it is better to place but do not tie the last 3-4 sutures until all are placed.

 **Tip!** Placing the tip of a right-angled clamp into the rectal lumen is a useful way of displaying the anterior rectum (especially for the distal edge) as you are closing the anterior row.

It is important to work from lateral to medial on each side so that you end up in the centre. Otherwise, you will have trouble lining up the edges. The proximal end is often much wider than the distal. This becomes apparent when closing the anterior layer. To overcome this, use the next top tip.

 **Top Tip!** The colon is usually wider than the rectum. Spacing the proximal bites wider apart will overcome most discrepancy. However, you should start doing this on the posterior row as otherwise there will be a large discrepancy when you get to the anterior row. If you have managed the discrepancy poorly, you may have to stitch the proximal end to itself in a T (Fig. 7.14b). A better alternative is to make a vertical incision in the midline of the anterior part of the distal rectal end to make it wider (Fig. 7.14c). When closed, this will stretch into a linear incision and avoids a T-junction so it should heal better. However, as the distal end may already be short, it may not be possible to do this. Note: Both of these options should rarely be necessary.

**Test:** During abdominal repair, the anastomosis can be tested by injecting air via a Foley catheter (balloon inflated 50 ml) in the lower rectum while clamping the sigmoid colon with your hand. The pelvis is first filled with saline and 60 ml of air is injected with a bladder syringe up the Foley catheter in the rectum which should be seen to distend. If there is a leak of air, it would be safer to do a colostomy in addition to inserting more sutures in the leaking area. The converse is also true. If there is no air leak on testing, this would indicate that you have achieved a good repair and a colostomy may be avoided.

### COMBINED ABDOMINO-PERINEAL (PULL-THROUGH) PROCEDURE FOR CIRCUMFERENTIAL DEFECTS

**Situation 1 (Fig. 7.15a):** The distal rectum can be visualized vaginally: Sometimes there will be a large gap between the proximal and distal end of the rectum. The distal end may be just a few centimetres above the external sphincter. In this case, the proximal end may have to be mobilized abdominally and then pulled through into the vagina. It can then be anastomosed (end-to-end) with the distal end (ano-rectum). This is relatively easy to do provided there is plenty of length on the rectum. Ensure the proximal end reaches beyond the pubic symphysis from the abdomen before you pull it through the pelvic floor.

If the anterior wall of the distal rectum is involved by a tear and a fistula, it may appear that it is almost completely absent. However, usually the anterior wall is partly retracted rather than absent. You have to anastomose the proximal end (anterior and posterior walls) to this (“posterior” wall). Just start posteriorly in the midline and work around on both sides. You have to gain more distance on the proximal edge by spacing the sutures further apart. If stenosis is developing, see Fig. 7.11c.

**Situation 2 (Fig. 7.15b):** The distal rectum cannot be approached vaginally i.e. the fistula is too high to approach vaginally and too low to anastomose abdominally i.e. there is not enough length of distal rectum to work with from above. A colo-anal anastomosis is performed. This method can be used for:

- (a) Post-radiotherapy fistulas
- (b) Obstetric fistulas: When doing an abdominal repair of a circumferential RVF, if you find that the distal end is too short or tears distally as you try to anastomose, then it is better to do a pull-through.

**Method:**

- The left colon is mobilized to include the splenic flexure. If there is already a sigmoid colostomy, this has to be taken down and closed.
- Incise the peritoneum to the right and then to the left of the rectum. Identify the left ureter.
- To separate the rectum from the vagina, first divide the peritoneum. Then pull up on the vagina/ uterus, while pushing down on the rectum.
- It is often easiest to transect the rectum at the site of the RVF and then mobilize the rectum proximally.
- Once the rectum is mobilized, place two strong sutures on either side of the rectum laterally which are used to pull it through to the anus. Do not twist the rectum. Use the two stay sutures to check for this.
- As the rectum will have been cut (from above) 4-8 cm above the dentate line, you need to excise distal rectal mucosa from below to leave a short ano-rectal ring for joining to the pulled through rectum; otherwise you cannot access from below to do the anastomosis. The mucosa is excised by injecting saline with diluted adrenaline under it and dividing it into 4-6 strips of 3-4 cm width. Starting posteriorly, make two longitudinal incisions into the rectal mucosa, and then a transverse incision 2-4 cm above the dentate line. Then with scissors undermine and excise the mucosa. This is repeated all around the rectum. Some mucosa will occasionally be left and this can lead to mucus and abscess formation. Some surgeons use the cautery to excise the mucosa.

- The anastomosis is performed trans-anally 2-4 cm above the dentate line. Use approximately 12 stitches of interrupted 2/0 Vicryl. Place sutures at 12, 3, 6 and 9 o'clock but do not tie. Then place sutures in between these but tie as you go. In this way, you have sutured the rectal ring to the anal ring all the way around, with the knots facing the lumen (Fig. 7.15b).
- Always do a defunctioning (transverse) colostomy or loop ileostomy.

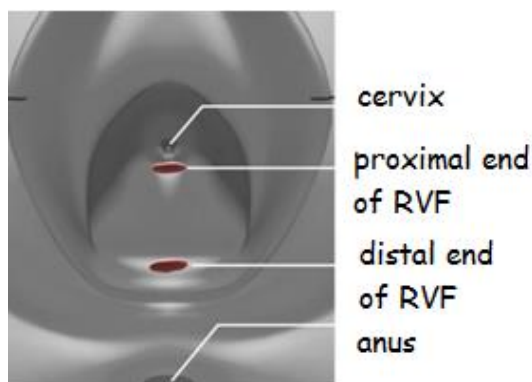


Fig. 7.15a: The type of defect that may require a pull-through procedure performed by a vaginal/perineal approach (Situation 1).

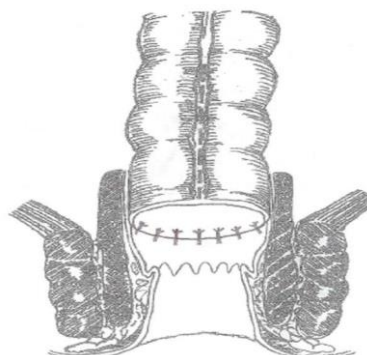


Fig. 7.15b: A colo-anal anastomosis which is performed 2-4 cm above the dentate line (Situation 2).

*Post-operative care:* if she develops a fever, you need to do a rectal examination and drain anything via anastomosis. If an abscess develops it is best to drain it proactively rather than to wait for it to drain spontaneously.

The following applies mainly to post-radiotherapy fistulas where it is often possible to divide the rectum at a lower level as the RVF is lower:

- Get into the plane behind (posterior and lateral to) the rectum to mobilize completely down to the pelvic floor. The plane separates the rectum from the sacrum and lies between:
  - The mesentery at the back and sides (posterior and lateral) of the rectum which is largely fatty tissue and blood vessels which is known as the mesorectum. It has a smooth bilobed surface.
  - The pre-sacral fascia. Cutting this layer exposes the sacral veins so if you see the blood vessels of the sacrum, it means you are in the wrong plane.
- By getting into this plane (known as the Holy Plane), there should be no bleeding whereas if you dissect too close to the rectum or sacrum, bleeding will occur. If in doubt, stay closer to the “serosa” of the rectum than the sacrum.
- In circumferential RVFs, you may hit the area where the RVF is stuck posteriorly as you go down this plane. It is then necessary to use sharp dissection to mobilize the rectum.
- Place one clamp transversely across the rectum as low as you can. Then by placing your fingers over the clamp, pull up on the rectum.



**Tip!** An assistant can place his finger in the rectum to help you identify the lower rectum from above.

- Transect the rectum as low as you can, ideally about 2-4 cm above the dentate line.
- You may have to then trim proximally to excise the fistula.
- If you are able to transect low, you do not then have to excise any rectum or rectal mucosa from below.

### LATE STENOSIS

In some cases, there is marked stenosis at the fistula site before any repair. If a colostomy is performed, the stenosis can become complete as stool is no longer dilating the site. I have seen several cases where a colostomy was performed for an RVF and eventually the rectum became completely stenosed. The RVF appeared to have “healed” and the dye test was negative. Only by doing a rectal examination could the stenosis be felt high up. The stenosis involves both the rectum and the surrounding tissues in the pelvis, at the level of the pelvic brim/sacral promontory. Resection of the involved stenosed area of the rectum with anastomosis has to be performed abdominally similar to circumferential RVF repair.



**Tip!** If there is uncertainty about stenosis, an examination under anaesthesia is indicated. Almost always you can feel the stenosis from below, especially in an anaesthetized patient.



**Tip!** When an RVF has been repaired and there is stenosis at the site of repair, if you can pass your finger through the stenosed area, the colostomy should be closed after 6 weeks, provided a dye test (done via the colostomy) shows no leak.

#### **POST-OPERATIVE CARE AFTER RVF REPAIR:**

- (a) *If vaginal approach:* Intravenous fluids only until flatus passed. This should be followed by oral fluids/light diet (e.g. soup, yoghurt) only until day 7. An alternative regime that is used is to allow the patient to drink the same day, thick fluids on day 1, light diet day 2 and normal diet with laxatives from day 3.
- (b) *If abdominal approach:* Start oral fluids when the stoma is working and start solid food once fluids are tolerated. The stoma is closed after 6 weeks. If you wait too long, the fistula site can become narrow, as it is not being dilated by faeces.

#### ***If stool leaks from the RVF repair site:***

- Irrigate the vagina with a syringe to keep it clean after any bowel motion. Get all the stool out. It is still possible that the RVF may heal. This can even be done by the patient herself after proper instruction. Combined with a low residue diet, irrigation may protect any VVF repair from breaking down and also increases the chances of RVF healing
- Consider doing a colostomy especially if you think the repeat repair will be difficult. With a colostomy, there is even a chance that the fistula may heal without further surgery.

*Case History:* A primiparous patient had a Caesarean section for obstructed labour with a dead baby. She developed a VVF and an RVF. Stool was also coming through the abdominal wound. At laparotomy, there was just a narrow rim of tissue joining the proximal and distal rectum at the site of the RVF. This was divided and the proximal end brought out as an end colostomy. After 5 months, the VVF was closed vaginally. At the same time, the rectum was re-anastomosed abdominally. At laparotomy, it was difficult to locate the proximal part of the distal rectum. A large Hegar dilator was passed up the anus into the rectum and this made it easy to find the rectum. After re-opening the distal rectum, an anastomosis was performed with interrupted sutures as described above.

### **(7.5) ANAL SPHINCTER TEAR (SECONDARY) REPAIR**

*The internal anal sphincter* is responsible for the resting tone of the anal canal. This smooth muscle group has the major responsibility for continence of liquid stool and flatus. It relaxes in response to filling of the rectum. Tears of the internal sphincter lead to passive soiling and flatus incontinence.

- The internal sphincter is in the distal 2.5 - 4 cm of the ano-rectal wall.
- In fresh tears, you can identify the internal sphincter just above the ano-rectal mucosa/serosa and it has a white, or pale and fish like appearance. It often retracts laterally and superiorly but can be identified most easily at the apex of the tear. i.e. the ends of a torn internal anal sphincter are often located lateral to the ano-rectal mucosa. It should be included in the second layer after the mucosal repair. Allis clamps can be placed on the ends of the retracted internal anal sphincter to facilitate repair.
- In old tears, it is difficult to identify the internal sphincter. If you close the ano-rectal wall in two layers, this may approximate the internal sphincter.

*The external anal sphincter* and the medial part of the levator ani (pubo-rectalis), both striated muscle groups, are mainly responsible for continence of solid stool. The external sphincter responds to the sudden filling of the rectum secondary to the peristalsis of the bowel.

- The external sphincter is red and meat-like and is 2.5 cm long. It is covered by a capsule and laterally is the ischio-anal fat.
- The length of the sphincter is the best predictor of continence as it is a high-pressure zone.
- Contraction of pubo-rectalis can compensate for a torn external sphincter for a while.

Patients who have tears to both the internal and external sphincters have more symptoms compared to those with tears of the external sphincter alone.

#### ***Diagnosis: If you are not sure if the sphincter is torn or not***

*Inspect:* With a partial tear of the external sphincter, look for absence of the skin folds anterior to the anus.

*Palpate:* Place the index finger in the rectum, and the thumb in the vagina. This will enable you to detect any loss of sphincter bulk, suggesting an underlying third or fourth degree tear.

*Move:* Ask the woman to contract her anal sphincter while performing a gentle rectal examination and any loss of tone will suggest an underlying sphincter defect.

***If the patient presents with an infected tear,*** you have to wait until it is clean before you can repair. It is best to debride aggressively, treat with antibiotics if indicated and give sitz baths 2-4 times daily. Adding detergent to



the water such as Omo is strongly recommended. The repair can be performed when the tissues look healthy. It is not necessary to wait 6 weeks or longer before repairing.

Reference: *Obstetric Trauma Surgery: sphincter ani rupture. Kees Waaldijk January 2016.*

### Pre-operative preparation

- Keep on fluids only for 1 to 2 days pre-operatively.
- Give an enema the day before to ensure the lower colon is empty. An enema given the morning of surgery often only provokes continuous passage of liquid stool during the operation. Alternatively, full oral bowel preparation may be used as described for RVF.
- A colostomy is usually only considered if there have been two failed repairs previously i.e. on the third attempt.
- Give intra-operative prophylactic antibiotics as the risk of infection is higher with secondary compared to primary repairs. Metronidazole alone or combined with gentamycin or a cephalosporin are the common ones used.

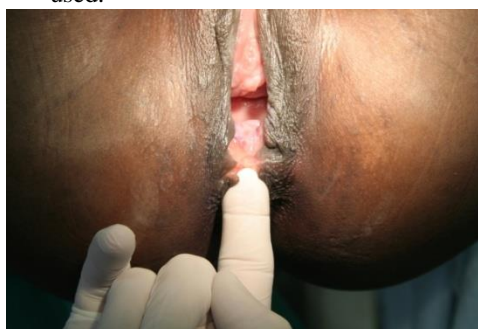


Fig. 7.16 a: Example of 4<sup>th</sup> degree tear.

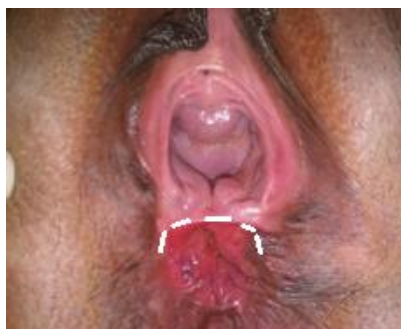
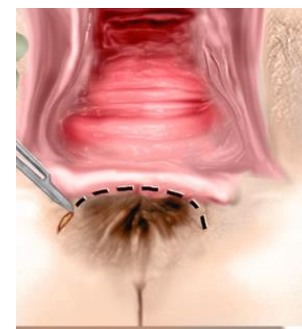
Fig. 7.16b: Shows the initial incision made to separate the vagina from the rectum.



There are 3 techniques in repairing these injuries:

- Do a limited dissection enough to just approximate the sphincters end-to-end: commonest method.
- Do a major dissection to allow overlapping of the sphincters.
- Approximate the sphincters with sutures without dissecting them out i.e. omit step 3 below.

### (STEP 1) INCISION

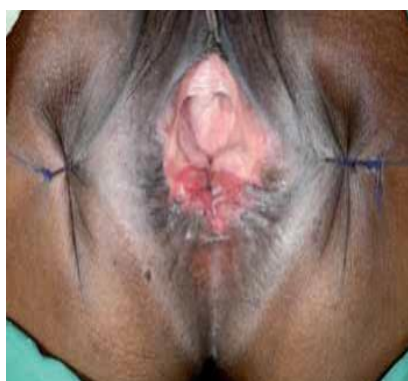

Fig. 7.17a: Shows a stay suture inserted on both sides. (K Waaldijk)

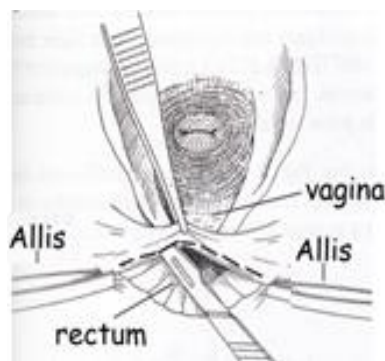
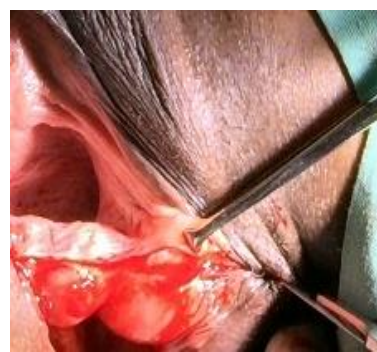

Fig. 7.17b + c: The incision is made at the junction of the vagina (pink) and the rectum/ anus (red).



- Infiltrate with a vasoconstrictor i.e. diluted adrenaline solution.
- Stretch the skin at the junction of the rectum and vagina between two Allis forceps as shown in Fig. 7.17b. Alternatively, place a stay stitch on each side from just lateral to the anterior rectal edge (at the level of the retracted sphincter ends) to the skin laterally. This stretches the anterior border of the anus (see Fig. 7.17a).
- With your left hand holding a toothed forceps, place these just inside the vagina to pull it up (7.17b).
- Make a transverse horizontal incision with a knife at the junction of the rectum and vagina – shown by the interrupted line or the red - pink junction (Fig. 7.17c). The options are:
  - (a) Extend the incision about 1 cm laterally onto the skin on each side (Fig. 7.17c) or
  - (b) Do not extend the incision onto the skin. Instead, go around postero-medially onto the rectum-skin junction for 1-2 cm (see Fig 7.16b). However, if you extend this too far posteriorly, it may compromise the blood supply to the anus. This method is easier to close and gives a better cosmetic result.
- You may need to excise a narrow strip of scarred rectal and vaginal mucosa that has healed together.

**(STEP 2) SEPARATE VAGINA FROM THE RECTUM**

Separate the vagina from the rectum for about 4 cm proximally, using a knife to cut the tissue off close to the vagina (Fig. 7.18c).

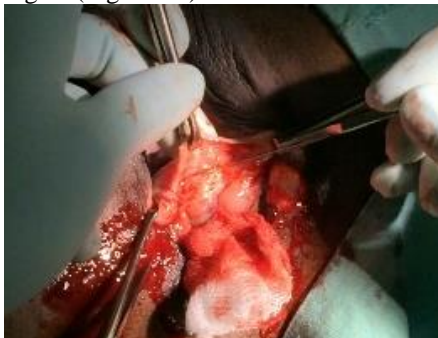

Fig. 7.18a: The vagina is being separated from the anus/ rectum with a knife. Finger is in the vagina.

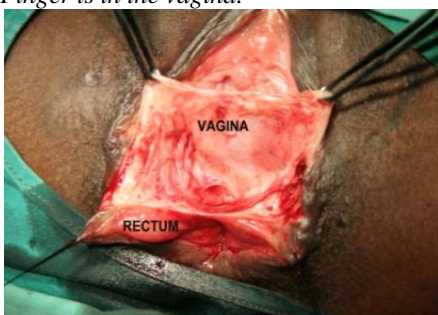

Fig. 7.18c: Aim to separate the vagina for 4-5 cm proximally.

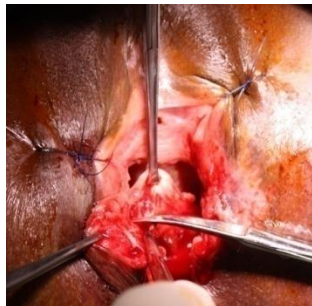


Fig. 7.18b: In this case, the vagina is being separated with scissors in the right hand and pickups in the left hand.

**⚠ Tip!** Keep your finger in the vagina and dissect close to this to avoid opening the rectum. Have Allis forceps on both the rectal and vaginal edges to help develop the plane of dissection.

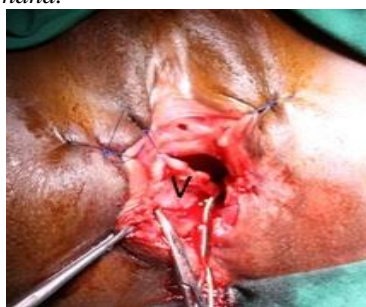

Fig. 7.18d: Once the vagina (marked V) is separated, place a stay suture on each side (right shown here) to retract the vagina for exposure.

**Tips to identify the external sphincter:** (this has to be read along with step 3)

The difficult part of the operation is to identify the two ends of the anal sphincter. Defining the boundaries of the anal sphincter is easier in fresh tears as opposed to old tears. There are two ways that help to define the sphincter:

- (1) Remember that the sphincter goes around the anus. The sphincter should appear as red/ purple muscle fibers coming from the postero- lateral direction. Using an Allis clamp, grasp where you think the sphincter should be i.e. just lateral to the rectum/ anus. It helps to direct the Allis clamp from medial to lateral (at a 45-degree angle) pushing the Allis head into the tissue where the end of the sphincter may be and then opening and grasping. Then pull this tissue medially. The tissue feels substantial and you can see the outer skin wrinkle as you grasp. Then with your finger in the anus (Fig. 7.20c), feel for the sphincter posteriorly and then at the sides. As you pull on the Allis (which is grasping the sphincter), feel if this tightens the posterior and lateral parts of the rectal/ anal wall. This is the most useful way to confirm you have identified the sphincter.
- (2) The fat of the ischio-rectal fossa lies lateral to the sphincter so if fat is seen, the sphincter should be medial. The sphincter lies between the anal mucosa and the fat.

**(STEP 3) DISSECT OUT THE SPHINCTER**

(a) *Limited dissection:* Most surgeons now do a more limited dissection of the sphincter i.e. pass an Allis forceps down on either side of the rectum, grasp the sphincter (confirmed on rectal examination as in Fig. 7.20c), and mobilize it just enough to approximate it.

(b) *More extensive dissection of sphincter:* Only performed if overlapping of the sphincter is planned.

- Holding the lateral edges of the initial incision above and below with Allis forceps, push scissors into the incision and open them in an anterior-posterior direction (Fig. 7.20a). Now you should see the fat which is lateral to the sphincter (Fig. 7.20b).
- With an Allis forceps go posteriorly just lateral to the rectum/ anus to pull up the sphincter.

Once identified and grasped, mobilize the sphincter circumferentially:

- (a) Posteriorly from the skin and anal mucosa: With an Allis on the anal edge, keep your index finger in the rectum to avoid button-holing the rectum as you dissect. Either use a knife or a partially opened scissors to free the tissues.

(b) Medially, laterally and anteriorly.

Stay close to the vagina and rectum all around as you mobilize the sphincter.

- The sphincter edges should be freed so that they come together in the midline without tension.

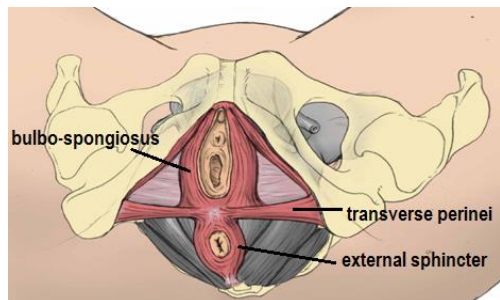


Fig. 7.19: Shows the normal anatomy.

The main structures that can be confused with the sphincter are the transverse perinei muscles. These come into the perineal body laterally whereas the sphincter approaches posteriorly. If you pull on the transverse perinei, you will stretch the lateral tissues and not feel traction with your finger in the rectum.

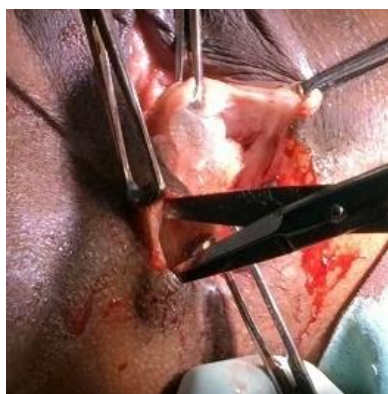

Fig. 7.20a: Scissors are inserted into the lateral part of the incision and opened longitudinally.

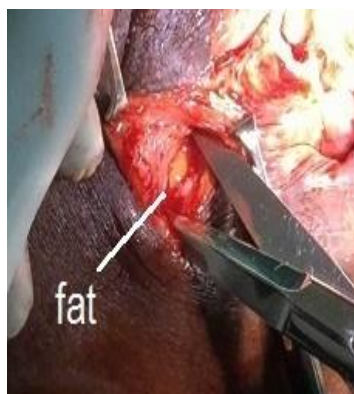

Fig. 7.20b: Lateral to the sphincter is ischio-rectal fat as seen here.

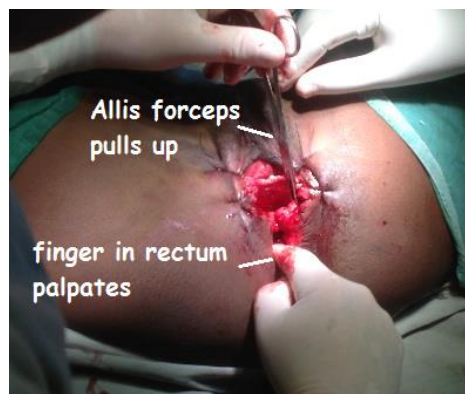


Fig. 7.20c: With your right index finger in the anus, palpate posteriorly as you pull up on the Allis forceps (holds the external sphincter) with your left hand.

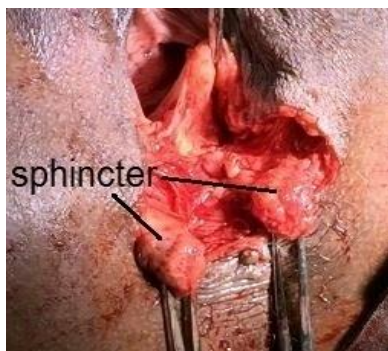
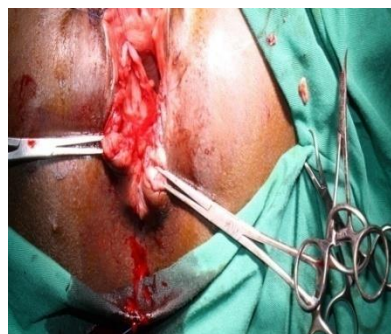

Fig. 7.21a+ b: The sphincter is mobilized and ready for approximation. A useful tip to keep the sphincter out of the way while closing the rectum is to retract the sphincter by placing it under tension. Insert artery forceps or a towel clip through one ring of the Allis forceps holding the sphincter and attach the artery or towel clip to the drapes out laterally as in the photograph on the right.



**Tip!** The levator muscle is seen proximal to the external sphincter. You can place several sutures to approximate the levator muscle across the midline before approximating the external sphincter.

#### (STEP 4) CLOSE THE RECTUM/ ANAL CANAL

This is done in two layers to reduce the risk of flatus leaking through the suture line with a one-layer closure.

*First layer:* Insert 2/0 or 3/0 Vicryl interrupted sutures every 3-4 mm with knots outside the lumen.

- The key is to suture in such a way that there is no mucosa protruding on the vaginal side i.e. invert the mucosa. Aim to get good bites mainly of pre-rectal fascia which provides strength and avoids the mucosa. The internal sphincter is often included in the first layer closure.
- Keep the short ends of the first layer of sutures on artery forceps to be used later.

- Start at the apex and work distally. It is important to keep suturing the rectum distal to the ano-cutaneous border (pink/ brown) so that you see the complete anal ring re-formed. If you stop prematurely, it will be very difficult to get sutures into this area later.
- If necessary, you can do the last stitch from the outside i.e. go in through the skin (1 cm bite) on one side and back out to the skin on the other side. This stitch is mattressed so go back to the initial side and tie.

Second layer of the ano-rectum is now placed as:

- A continuous or interrupted stitch(es) which is inserted parallel to the edges and quite lateral. This layer is placed from proximal to distal.
  - Tie the second layer sutures to the short ends of the first layer (interrupted continuous) if a continuous suture is used.
- Sometimes only one layer is possible and this is acceptable.
- Remove the stay suture on the skin now to remove any stretch on the sphincter.

**(STEP 5) APPROXIMATE THE EXTERNAL SPHINCTER:** there are three methods used:

- (a) **Simple end to end anastomosis** (non-overlapping): This is the commonest method used. In this case, after dissecting the sphincter, either place 2-3 interrupted mattress sutures (PDS 2/0 or 0 is preferable to Vicryl) to join the ends of the sphincter together or insert several interrupted sutures as in Fig, 7.21c.

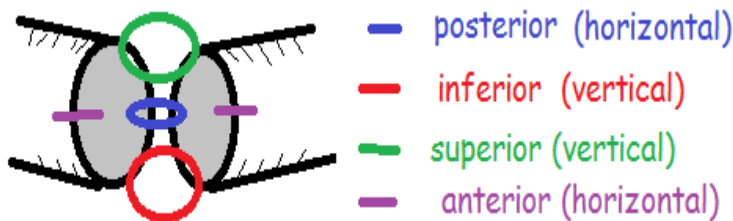


Fig. 7.21c: The sphincter is approximated with figure of 8 sutures x 4 placed in a specific order - PISA. (P) Posterior stitch joins the posterior part together. (I) Inferior suture (S) Superior suture (A) Anterior suture. Extra sutures may be placed if there is a lot of tissue.

- (b) **Technique for approximating sphincter without dissecting it out:** The tissue is approximated by passing the needle into the area that you know the sphincter will be. Three separate sutures are inserted to approximate the external sphincter:

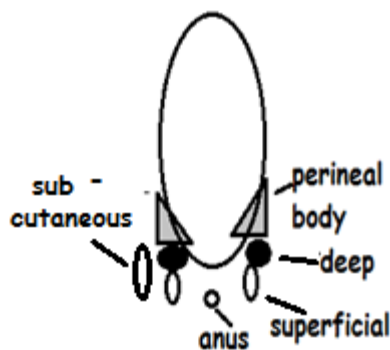


Fig 7.22a: The perineal body is more anterior than the external sphincter.

- *The superficial part* of the external sphincter is the part closest to the anal canal and just under the skin. This is inserted deep and parallel to the lowest skin beside the ano-cutaneous junction. When this is tied, you can see the anal ring re-formed fully. Leave the short end of the suture long on an artery forceps. Light traction on this helps place the next suture.
- *The deep part* is more proximal to (or above) the superficial part. Traction on the superficial sphincter suture makes it easier to place the deep one. This is also inserted deep and parallel to the skin but just above the superficial part.
- *The subcutaneous part:* The needle is inserted just above the deep part. The bite is taken by going out more laterally and downwards. You should be able to see the needle scraping just under the skin.

(c) **Overlapping technique:**

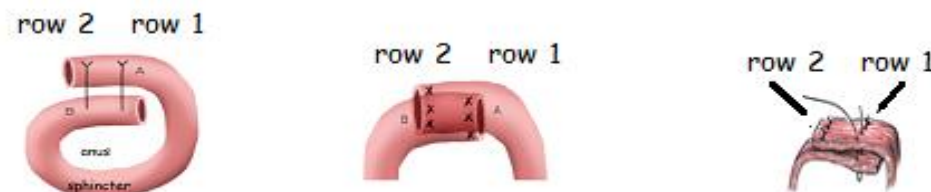
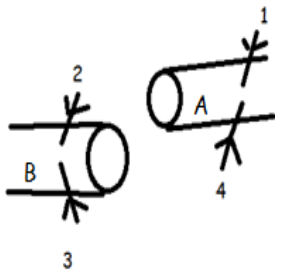



Fig. 7.22b: Shows how the sphincter is overlapped. The left side of the sphincter (A) being pulled over the right side (B). Fig. 7.22c + d: is a view from above to show where the 3 sutures (marked x) are placed for each row.

 <p>Fig. 7.22e: Shows the suture for the first overlapping row.</p>	<p>For the first row, 2 - 3 sutures are inserted, one proximal (posterior) and one distal (anterior) and one in between (Fig. 7.22d). Place and clip all 3 before tying. Do not tie too tight to avoid excessive tension on the sphincter. This should overlap the sphincter.</p> <p>To get the sphincter to overlap, each of these is placed in a specific way taking four bites (Fig. 7.22e):</p> <ul style="list-style-type: none"> <li>Bite 1 = on side A from top down at least 1.5-2 cm back or as far as it allows you to.</li> <li>Bite 2 = on side B from top down about 1 cm from the edge.</li> <li>Bite 3 = on side B go from bottom to top about 1 cm from the edge.</li> <li>Bite 4 = on side A, go from bottom to top at least 1.5 cm back or as far as it allows you to.</li> </ul> <p>The second row needs to be medial to the first row (Fig. 7.22b, c, d). Just place two simple sutures to tie down the overlapping part. Tie each as you place them.</p>
--	---

**(STEP 6) APPROXIMATE THE PERINEAL MUSCLES FROM SIDE TO SIDE.**

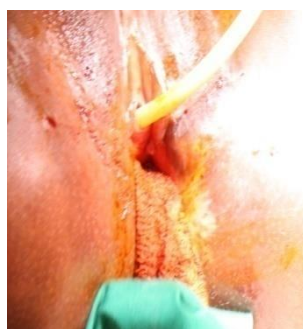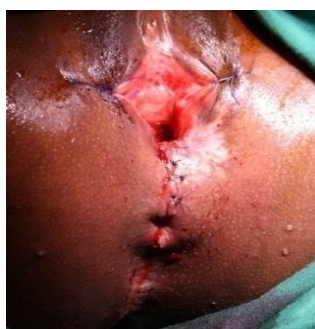Aim for three sutures in the perineal body which may include levator ani.

- The first is inserted just above (i.e. superficial to) the external sphincter.
- The next is inserted proximal/ above this one. However, if you insert too many sutures proximally, it will narrow the vagina. Use a 36 mm needle to get good bites. The sutures are inserted horizontally taking a bite on each side.

	<ul style="list-style-type: none"> <li>• If you build up the perineum with too many sutures before you start closing the vagina, you can have difficulty getting access to close the vagina. If necessary, start closing the vagina before you place too many sutures in the perineum.</li> <li>• The anal opening should not be too tight and should admit one finger easily. Therefore, narrowing should be avoided when approximating the anal canal and the sphincter. You need to assess this early when closing the ano- rectal mucosa and then at each subsequent step in the closure. If the opening is too narrow, this may cause faeces to leak through the repair above the anus and disrupt the closure.</li> </ul>
--	---

**(STEP 7) REPAIR THE VAGINA AND PERINEAL SKIN**

Close the vagina longitudinally, even though the initial opening was transverse. The vaginal opening should be able to admit at least two fingers. Avoid closing the vagina too tightly to allow for drainage and reduce the risk of sepsis. You only need to achieve haemostasis. Also, the perineal skin is closed loosely. Consider inserting a drain under the skin.



**! Tip!** Avoid closing the vagina or the perineal skin fully as this will often lead to sepsis. It makes sense to leave part of the vaginal aspect open for drainage provided you have secured haemostasis. Place a stitch at the apex of the vagina. Then leave a gap of 1-2 cm. Alternatively, place a drain under the skin.

Fig. 7.22f: Shows the perineal skin approximated. Fig. 7.22g: Gauze soaked in Betadine over the wound.

<p><b>Summary of 4th degree tear repair</b></p> <p>(a) <i>Rectum/ anal canal</i>: two layers – first interrupted; second interrupted or continuous 2/0 or 3/0 Vicryl.</p> <p>(b) <i>Sphincter</i>: approximate with 2/0 or 0 PDS interrupted sutures for end to end closure.</p> <p>(c) <i>Perineal muscles</i>: interrupted 0 or 1 Vicryl.</p> <p>(d) <i>Vagina and perineal skin</i>: approximate as loosely as possible.</p>
---

**Postoperative Care**

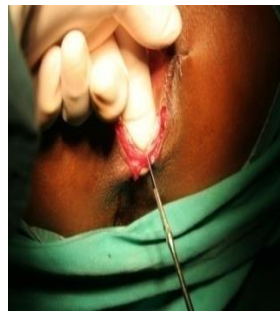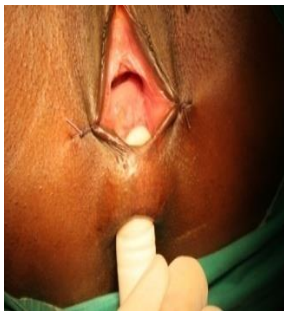- (a) *Diet*: A balance should be found, avoiding constipation which is painful, and diarrhea which is difficult to clean. There are two approaches but no clear evidence for either:

- Commence normal diet on day 1-2.
  - Keep on fluids only for 3-5 days. This avoids stress on the repair with the passage of stool. Soup or yoghurt is allowed. This allows the wound to be healing well before any stool is passed.
- (b) *Hygiene:* Wash with water after each bowel motion to avoid faecal matter on the wound and then dry. Avoid prolonged soaking as this will encourage suture breakdown. Sitz baths are only used for infected cases.
- (c) *Avoid constipation:* A stool softener (e.g. lactulose 30 ml 3 times/ day or bisacodyl/ Dulcolax 2 x 5 mg tablets daily) can be started once the patient is on a full diet and continued for a week. Keep her in hospital until she has passed 2 bowel motions.
- (d) *Avoid urine retention:* this is a common problem after this operation so keep the catheter in for two days although some units remove it on the first day.

**Complications:**

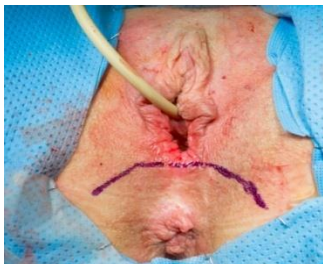- You may see superficial skin separation in the first 2 weeks post-operatively. Do not confuse this with total breakdown, as the sphincter is usually intact. Maintaining hygiene is all that is necessary and reassure the patient.
- If the wound becomes infected, remove the skin sutures and prescribe frequent sitz baths.

**(7.6) ANAL SPHINCTER TEAR REPAIR WITH RVF OR POSTERIOR DEFECTS**

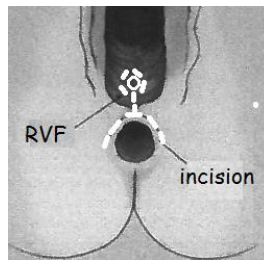


- (1) If the RVF is really the unhealed apex of a 4<sup>th</sup> degree tear which has partially healed i.e. there is almost no sphincter tissue intact: Convert RVF into a 4<sup>th</sup> degree tear by incising the bridge of tissue (Fig. 7.23) and carry out the repair as in section 7.5. This approach (fistulotomy = cutting the entire bridge of perineal tissue superficial to the fistula) can also be used for any fistula that is very distal and superficial.

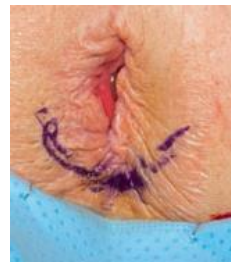*Fig. 7.23a +b: Show a low RVF which is converted to a 4<sup>th</sup> degree tear. A trans-perineal approach would have been a better option here as the bridge of tissue is large and the sphincter is probably intact at least partially.*



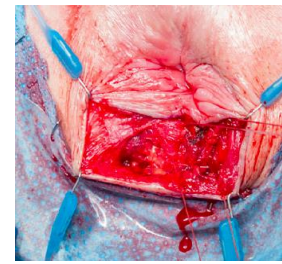
*Fig. 7.24: Shows the incision for repairing a sphincter tear alone.*



*Fig. 7.25: Approach to separate RVF and sphincter repair.*



*Fig. 7.26: Shows the incision for repair of a posterior defect of the sphincter in addition to an anterior defect.*



*Fig. 7.27: Shows the incision made and the sphincter being re-approximated.*

- (2) If there is a mid-vaginal RVF with a very deficient sphincter. In this situation, an incision is made as shown in Fig. 7.25. Then repair the RVF and the sphincter separately with good exposure of both. This is a variation of the trans-perineal approach described in section 7.1B.
- (3) If there is a sphincter tear alone (3<sup>rd</sup> degree), this can be approached as in Fig. 7.24.
- (4) **Combined Anterior and Posterior Anal Sphincter Repair:** If after repair of the anterior part of the sphincter, the posterior anus is gaping (see Fig. 7.26), then there is probably a defect of the posterior sphincter. Sutures are placed to approximate the posterior fibres of the anal sphincter (see Fig. 7.27). Keep a finger in the rectum to avoid penetrating the rectal wall. Also, approximate the puborectalis and pubococcygeus muscles posteriorly.